



OPEN ACCESS

Pathological diagnostic criterion of blood and lymphatic vessel invasion in colorectal cancer: a framework for developing an objective pathological diagnostic system using the Delphi method, from the Pathology Working Group of the Japanese Society for Cancer of the Colon and Rectum

Motohiro Kojima,¹ Hideyuki Shimazaki,² Keiichi Iwaya,² Masayoshi Kage,³ Jun Akiba,⁴ Yasuo Ohkura,⁵ Shinichiro Horiguchi,⁶ Kohei Shomori,⁷ Ryoji Kushima,⁸ Yoichi Ajioka,⁹ Shogo Nomura,¹⁰ Atsushi Ochiai¹

► Additional material is published online only. To view please visit the journal online (<http://dx.doi.org/10.1136/jclinpath-2012-201076>).

For numbered affiliations see end of article.

Correspondence to

Dr Atsushi Ochiai, Pathology Division, Research Center for Innovative Oncology, National Cancer Center Hospital East, 6-5-1 Kashiwanoha, Kashiwa, Chiba 277-8577, Japan; aochiai@east.ncc.go.jp

Received 20 July 2012

Revised 25 December 2012

Accepted 8 January 2013

Published Online First

16 April 2013



Open Access
Scan to access more
free content



► <http://dx.doi.org/10.1136/jclinpath-2013-201587>

To cite: Kojima M, Shimazaki H, Iwaya K, et al. *J Clin Pathol* 2013;**66**:551–558.

ABSTRACT

Aims The goal of this study is to create an objective pathological diagnostic system for blood and lymphatic vessel invasion (BLI).

Methods 1450 surgically resected colorectal cancer specimens from eight hospitals were reviewed. Our first step was to compare the current practice of pathology assessment among eight hospitals. Then, H&E stained slides with or without histochemical/immunohistochemical staining were assessed by eight pathologists and concordance of BLI diagnosis was checked. In addition, histological findings associated with BLI having good concordance were reviewed. Based on these results, framework for developing diagnostic criterion was developed, using the Delphi method. The new criterion was evaluated using 40 colorectal cancer specimens.

Results Frequency of BLI diagnoses, number of blocks obtained and stained for assessment of BLI varied among eight hospitals. Concordance was low for BLI diagnosis and was not any better when histochemical/immunohistochemical staining was provided. All histological findings associated with BLI from H&E staining were poor in agreement. However, observation of elastica-stained internal elastic membrane covering more than half of the circumference surrounding the tumour cluster as well as the presence of D2-40-stained endothelial cells covering more than half of the circumference surrounding the tumour cluster showed high concordance. Based on this observation, we developed a framework for pathological diagnostic criterion, using the Delphi method. This criterion was found to be useful in improving concordance of BLI diagnosis.

Conclusions A framework for pathological diagnostic criterion was developed by reviewing concordance and using the Delphi method. The criterion developed may serve as the basis for creating a standardised procedure for pathological diagnosis.

INTRODUCTION

Blood and lymphatic vessel invasion (BLI) in colorectal cancer (CRC) are known to be strong risk factors correlated with poor outcome. Since it was first reported by Brown *et al* in 1938, numerous

studies have been conducted on BLI. BLI is adopted in TNM Classification of Malignant Tumours and College of American Pathologists Consensus Statement in pathology reports.^{1–4} Assessment of BLI enables identifying patients with high risk within the same TNM stage and therapeutic strategy can be tailored accordingly, especially for patients with Stage II CRC and patients with endoscopically resected pT1.^{5–7} Observation of BLI, however, is also known for its weakness, which is high interobserver variability. Many articles report poor interobserver concordance of BLI assessment and no solution has been offered so far.^{8–10} One solution may be to use elastica for histochemical staining or D2-40 for immunohistochemical staining of internal elastic lamina of vessel and lymphatic endothelium.^{11–15} Another solution may be to take a conventional approach to develop a framework for diagnostic criterion, through formal procedure to reach consensus, gain support and understanding of pathologists worldwide.¹⁶ It was under this concept that pathologists belonging to the Japanese Society for Cancer of the Colon and Rectum decided to join hands and took a comprehensive approach as follows: (1) review current practice of pathologists' assessment including sampling methods, staining methods and BLI in different medical institutions (2) evaluate concordance of BLI diagnosis and histological findings associated with BLI (3) develop a framework for diagnostic criterion using the Delphi method, with data from current practice and (4) conduct a concordance study to evaluate the usefulness of the new criterion. Our attempt was to develop a framework for an objective criterion to assess BLI, in order to improve concordance in all settings.

MATERIALS AND METHODS

Multicentre, retrospective review of pathological assessment at different departments of pathology

A total of 1450 patients with CRC who underwent surgical resection in 2003 from eight institutions under the Japanese Society for Cancer of the Colon and Rectum were reviewed. Clinicopathological factors including the TNM stage according to the

fifth edition of TNM classification,³ the presence of BLI, number of paraffin blocks taken to examine primary tumours, use of megablock, tangential tissue sectioning, histochemical staining and immunohistochemical staining were reviewed and compared.¹⁷ The range of histochemical staining and antibody used for immunohistochemical staining were also reviewed.

Interobserver study

Eighty consecutive, surgically resected specimens of Stage II CRC according to the seventh edition of TNM classification⁴ between 2003 and 2005 from the National Cancer Center Hospital East were used for the interobserver study. Eight pathologists from eight institutions assessed the slides. Specimens for pathological assessment were divided into six cohorts as follows (table 1) and concordance of diagnosis was reviewed. Cohort 1: H&E-stained slides without any guiding criteria. Cohort 2: H&E-stained slides without any criteria, but focus on designated area of lesion. Assessment was later checked to see which histological findings associated with BLI had good agreement. Concordance of assessment for designated area was also reviewed (figure 1). Cohort 3: H&E-stained, elastica-stained and D2-40-stained slides. Histochemical and immunohistochemical staining without any guiding criteria. Cohort 4: H&E-stained, elastica-stained and D2-40-stained slides. Histochemical and immunohistochemical staining without any guiding criteria but focus on designated area of lesion (figure 1). Observation was later checked to determine which slides of H&E, histochemical or immunohistochemical staining associated with BLI diagnosis had good concordance. Concordance of assessment for designated area of lesion was also reviewed. Cohort 5: H&E-stained, elastic-stained and D2-40-stained slides. Histochemical and immunohistochemical staining and our new criterion were used for assessment. Finally, for Cohort 6, the same H&E-stained, elastic-stained and D2-40-stained slides used in Cohort 3 were assessed by the pathologists (who were unaware of reviewing the same slides) to check diagnostic agreement of histochemical and immunohistochemical staining using our new criterion. Cohorts 1, 3, 5 and 6 each consisted of 20 CRC specimens and Cohorts 2 and 4 each consisted of 10 CRC specimens. H&E-stained slides and slides

of largest slice from blocks of specimen including the deepest invasive area of tumour were used in Cohorts 1, 3, 5 and 6, while one representative slide of the tumour was used in Cohorts 2 and 4. In Cohorts 2 and 4, assessment of designated area was reviewed to evaluate the agreement of BLI diagnosis. Three areas of lesion containing histological tumour cluster surrounded by some space or fibrous rim-like vascular structure were chosen randomly and marked with ink. Since the designated area was very small, virtual slides were used to indicate with an arrow where assessment should be made (figure 1). In Cohorts 1, 3, 5 and 6 the 'presence' or 'absence' of BLI was reported. In Cohorts 2 and 4, assessment of designated area was made as 'blood vessel invasion', 'lymphatic vessel invasion' or 'neither'. In Cohorts 2 and 4, histological findings associated with the diagnosis of BLI were collected. This was reviewed thoroughly in a meeting and was recorded in the survey sheet, as either 'present' or 'absent' (table 2).

Developing diagnostic criteria using the Delphi method

Four rounds of consensus meetings, participated by eight pathologists were held as shown in figure 2. Before the meeting, a survey on histological, histochemical and immunohistochemical diagnostic criteria of BLI was prepared. All pathologists were requested to answer the survey anonymously and send it by mail after the meeting.¹⁶ There were a total of 34 questions: 2 on the definition of BLI, 7 on the assessment of BLI, 4 on the use of histochemical and immunohistochemical staining, 8 on assessment of blood vessel invasion and 13 on the assessment of lymphatic vessel invasion (table 3). Scoring was based on 1 to 6 Likert scale (1=strong disagreement, 2=moderate disagreement, 3=some disagreement, 4=some agreement, 5=moderate agreement, 6=strong agreement), maximum score being 6 points. Scores of 5 and 6 were regarded as 'agreement'. Consensus was considered to be achieved when over 80% of the participants' scores resulted in 'agreement', based on the previously described scoring method.^{18–20} Four rounds of meetings with active discussion took place and surveys were conducted three times, after the second and third rounds of meetings, as shown in figure 2. At the beginning of the second and third rounds of meetings, interim results of survey were reported to the

Table 1 Details of cohorts and concordance of blood and lymphatic vessel invasion (BLI)

H&E staining	D2-40 and elastica staining	Designated area of lesion	Criterion		κ Value	95% CI	Positive ratio (%)
Cohort 1							
+	—	—	—	Agreement in blood vessel invasion	0.524	0.441 to 0.606	28.1
+	—	—	—	Agreement in lymphatic vessel invasion	0.216	0.133 to 0.299	32.5
Cohort 2							
+	—	+	—	Agreement in BLI	0.466		
Cohort 3							
+	+	—	—	Agreement in blood vessel invasion	0.502	0.419 to 0.584	73.8
+	+	—	—	Agreement in lymphatic vessel invasion	0.153	0.071 to 0.236	33.8
Cohort 4							
+	+	+	—	Agreement in BLI	0.622		
Cohort 5							
+	+	—	+	Agreement in blood vessel invasion	0.547	0.464 to 0.630	42.5
+	+	—	+	Agreement in lymphatic vessel invasion	0.492	0.409 to 0.575	26.9
Cohort 6							
+	+	—	+	Agreement in blood vessel invasion	0.617	0.534 to 0.700	75.6
+	+	—	+	Agreement in lymphatic vessel invasion	0.618	0.534 to 0.700	31.9

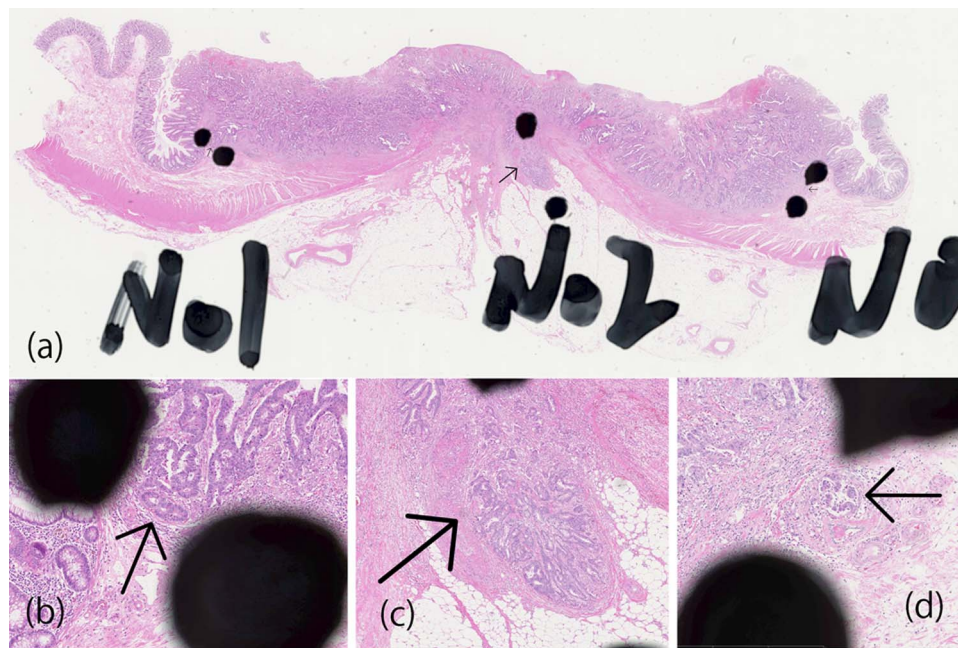


Figure 1 (A–D) A case from Cohort 2. In Cohorts 2, 4, three regions of interest within the histological tumour cluster with surrounding space or fibrous rim-like vascular structure were chosen randomly and marked with ink near the lesion (A). The lesion to be reviewed was indicated with an arrow on the virtual slides (B–D). Eight pathologists reviewed the slides. The assessment for each of the indicated lesions was reported as 'blood vessel invasion', 'lymphatic vessel invasion' or 'neither'. Furthermore, pathological findings associated with the diagnosis of blood and lymphatic vessel invasion were studied. Reviewers recorded their interpretations of the indicated lesion using the query sheet, answering the questions as 'present' or 'absent'.

participants to facilitate building consensus on key histological findings with high concordance. For findings that failed to present immediate agreement, further discussion took place and the next vote was performed. Consistent with the Delphi method, some questions in the survey were modified to enable building general agreement.¹⁸ After the third round of meetings,

the findings for which consensus had been reached were summarised and new diagnostic criterion was developed.

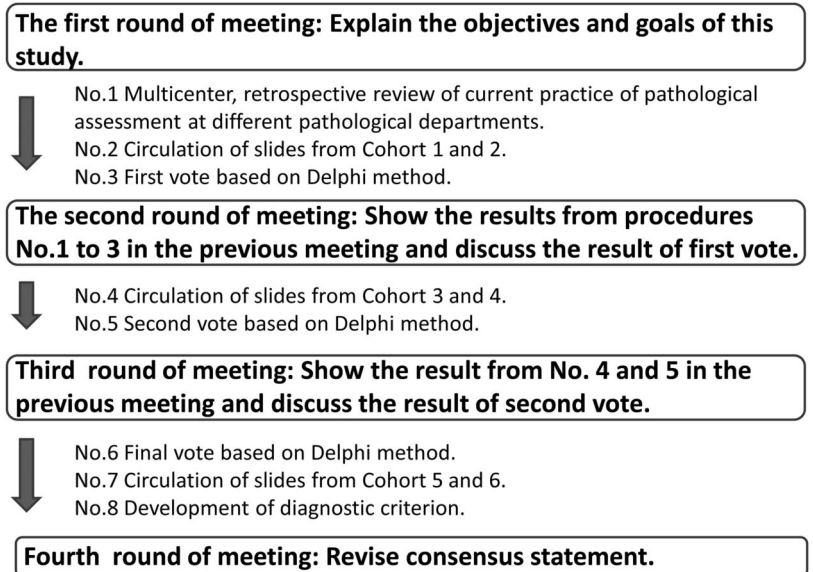
Statistical analysis

The concordance reached by pathologists on rating tumour invasion was evaluated using κ coefficients. Using %mk SAS macro, we

Table 2 Concordance of histological findings associated with the blood and lymphatic vessel invasion

Histological findings	κ Value	95% CI
Cohort 2		
Presence of space around tumour nests	0.492	0.424 to 0.560
Presence of endothelium around tumour nests	0.518	0.451 to 0.586
Presence of vascular smooth muscle around tumour nests	0.412	0.344 to 0.479
Presence of spicula at the periphery of tumour nests	0.308	0.240 to 0.376
Presence of lymphatic fluid in peritumoural space	0.454	0.386 to 0.522
Presence of blood cells in peritumoural space	0.395	0.327 to 0.462
Difficult to distinguish blood and lymphatic vessel	0.064	−0.033 to 0.132
Presence of continuity in normal blood or lymphatic vessel	0.276	0.209 to 0.344
Cohort 4		
Presence of space around tumour nests	0.471	0.404 to 0.539
Presence of endothelium around tumour nests	0.269	0.201 to 0.336
Presence of vascular smooth muscle around tumour nests	0.372	0.305 to 0.440
Presence of spicula at the periphery of tumour nests	0.002	−0.066 to 0.069
Presence of lymphatic fluid in peritumoural space	0.142	0.075 to 0.210
Presence of blood cells in peritumoural space	0.055	−0.013 to 0.122
Difficult to distinguish blood and lymphatic vessel	0.055	−0.013 to 0.123
Presence of continuity in normal blood or lymphatic vessel	0.150	0.082 to 0.217
Growth along with normal artery	0.491	0.424 to 0.559
Presence of elastica-stained internal elastic membrane covering more than half of the circumference surrounding the tumour cluster	0.801	0.734 to 0.869
Presence of D2-40 positive cells covering more than half of the circumference surrounding the tumour cluster	0.451	0.383 to 0.518
Presence of D2-40 positive endothelial cells covering more than half of the circumference surrounding the tumour cluster	0.682	0.615 to 0.750

Figure 2 Time flow for consensus development.



estimated the Fleiss type multi-rater κ coefficient and corresponding 95% CI.²¹ All statistical analyses was performed with SAS Release V.9.3 (SAS Institute, Inc, Cary, North Carolina, USA).

RESULTS

Multicentre retrospective review of current practice of pathological assessments

The result of the study is shown in table 4 and figure 3. The total number of cases reviewed in this study by eight institutions ranged from 54 to 441, of which 51.0–72.5% were colon cancer, 53.5–68.0% were male patients, and their average age was between 63 years and 68 years. The average number of paraffin blocks used for primary tumour pathological assessment varied widely among institutions, ranging from 4.8 blocks to 34.4 blocks. Use of histochemical staining and immunostaining was also different among eight institutions. And the range of histochemical staining performed was also different. Antibody used in immunohistochemical staining was D2-40 in three institutions. And one institution used D2-40 and alpha-smooth muscle actin (SMA). Figure 3 shows the results of a retrospective review of the stage and assessment of BLI. Although the stage distributions were similar among the eight institutions (Stage 0, I; 19.8–28.0%, Stage II; 10.2–17.4%, Stage III; 12.1–21.5% and Stage IV; 3.0–9.9%), substantial difference was noted on the presence of BLI (lymphatic vessel invasion; 18.9–74.8%, blood vessel invasion; 17.7–66.7%). None of the institutions in this study used megablock or tangential sectioning.

Interobserver study and development of diagnostic criterion using the Delphi method

The result of the interobserver study is shown in table 1. After the first round of meeting, Cohorts 1 and 2 were given only H&E stained slides without any additional staining or guiding criteria. The concordance of assessment of blood vessel invasion was moderate and it was low for lymphatic vessel invasion. This was not any better when pathologists in Cohort 2 were asked to focus on the designated area. Furthermore, the concordance of all histological findings associated with BLI was low in Cohort 2 (table 2). Diagnosis of BLI is based on multiple histological findings considered to be associated with BLI, most of which were included in this study as shown in table 2. Consistent diagnosis of BLI only with H&E-stained slides seemed to be difficult to achieve and this

was informed to the pathologists during the second round of meetings. It was then decided to distribute H&E-stained slides as well as the histochemical and immunohistochemical staining, without any guiding criteria (Cohorts 3 and 4). Although this increased positive findings of blood vessel invasion in Cohort 3, it did not improve the concordance of BLI diagnosis. In Cohort 4, concordance improved for the designated area. Interestingly, we found few histochemical and immunohistochemical findings associated with the diagnosis of BLI having good agreement (table 2). This was reported to pathologists during the third round of meetings and it was agreed that they should be included in the diagnostic criteria of BLI (table 3). Pathologists summarised the findings which they were able to agree upon and new diagnostic criterion was developed with active discussion (box 1). Finally, the use of the new criterion was evaluated with Cohorts 5 and 6. There was a remarkable improvement in concordance in Cohort 5 ($\kappa=0.547$ for blood vessel invasion, $\kappa=0.492$ for lymphatic vessel invasion), as well as in Cohort 6 ($\kappa=0.617$ for blood vessel invasion, $\kappa=0.618$ for lymphatic vessel invasion), which used the same slide as in Cohort 3 ($\kappa=0.502$ for blood vessel invasion, $\kappa=0.153$ for lymphatic vessel invasion). This serves as direct evidence on the usefulness of new criterion in improving agreement in BLI diagnosis (table 1).

DISCUSSION

The need for a diagnostic criterion which enables a standardised and objective diagnosis is clear. Our attempt was to provide a framework for developing a consensus-based criterion to be used in different pathological settings through this study. BLI are distinct pathological factors and have different clinicopathological implications.²² There are, however, some common morphologies such as the presence of endothelium or cavity, and distinct identification of small venules and lymphatic vessel is often difficult. There is also the problem of interobserver variability.² BLIs are strong risk factors in many types of cancer. In CRC, BLIs can be used as a criterion to determine the need for adjuvant therapy in Stage II cases, which account for a significant proportion of CRC cases (27.1% in this study). For endoscopically resected pT1 cases, BLIs are reported to be risk factors of lymph node metastasis and can be used as a criterion for making a decision of surgical resection. In this study, we tried to solve interobserver variabilities in BLI. The criterion that we developed may be useful for achieving

Table 3 Queries and consensus-building using the Delphi method

No.	Query	Result of vote
	Definition	
1	Lymphatic vessel invasion is defined as invasion of tumour cells into lymphatic vessels	Agreement (100%)
2	Blood vessel invasion is defined as invasion of tumour cells into blood vessels	Agreement (100%)
	Assessment of BLI	
1	Scanning at 4× magnification should be used to identify suspected lesion. Then further assessment should be made at higher magnification	Agreement (87.5%)
2	BLI should not be determined in lesions presenting desmoplastic reaction	No agreement (50.0%)
3	BLI should not be determined in lesions with spicula in the space between tumour nest and stroma	Agreement (87.5%)
4	Lymphatic fluid, macrophage or blood cells in the space between tumour nests and stroma should be determined as BLI	No agreement (50.0%)
5	A tumour cluster with space around the cluster, but with vague periphery should not be determined as BLI	No agreement (25.0%)
6	Assessment of BLI should be performed in the invasive front of tumour	No agreement (50.0%)
7	Assessment of BLI should be performed with largest section containing the deepest invasive area of tumour	No agreement (50.0%)
	Staining for assessment of BLI	
1	Histochemical staining for assessment of blood vessel invasion should be performed with a whole section from the largest slice containing the deepest invasive area of the tumour	No agreement (50.0%)
2	Histochemical staining for assessment of blood vessel invasion should be performed with a section representative of the tumour	No agreement (25.0%)
3	Immunohistochemical staining for assessment of blood vessel invasion should be performed with a whole section from the largest slice containing the deepest invasive area of the tumour	No agreement (50.0%)
4	Histochemical staining for assessment of blood vessel invasion should be performed with a section representative of the tumour	No agreement (25.0%)
	Assessment of blood vessel invasion	
1	Elastica-stained internal elastic membrane without space around the tumour cluster should be determined as blood vessel invasion	Agreement (87.5%)
2	Elastica-stained internal elastic membrane without vascular endothelium around the tumour cluster should be determined as blood vessel invasion	Agreement (87.5%)
3	In elastica staining, thick arteries surrounded by the tumour cluster should be identified. If elastica-stained internal elastic membrane covering more than half of the circumference surrounding the tumour cluster is observed, the lesion should be diagnosed as blood vessel invasion	Agreement (87.5%)
4	Even without the presence of arteries, if elastica-stained internal elastic membrane covering more than half of the circumference surrounding the tumour cluster is observed, the lesion should be determined as blood vessel invasion	Agreement (87.5%)
5	Elastica-stained internal elastic membrane covering more than half of the circumference surrounding the tumour cluster without other vascular structure (ie, smooth muscle) is determined as blood vessel invasion	Agreement (87.5%)
6	Elastica-stained internal elastic membrane covering more than half of the circumference surrounding the tumour cluster without endothelial cells in H&E staining should not be determined as blood vessel invasion	No agreement (12.5%)
7	Tumour invasion into the elastica-stained vessel should be determined as blood vessel invasion	Agreement (100%)
8	Elastica-stained internal elastic membrane not covering the circumference surrounding the tumour cluster should not be determined as blood vessel invasion	No agreement (12.5%)
	Assessment of lymphatic vessel invasion	
1	An indistinguishable lesion should not be determined as lymphatic vessel invasion	Agreement (100%)
2	A tumour extending along Auerbach's neural plexus should not be determined as lymphatic vessel invasion	No agreement (75.0%)
3	A lumen with mucin should not be determined as a lymphatic vessel in case of mucinous carcinoma	No agreement (37.5%)
4	Lymphatic vessel invasion should not be determined in a lesion with small cancer cell cluster and desmoplastic reaction	No agreement (50.0%)
5	Small vessels indistinguishable between lymphatic and blood vessels should be determined as lymphatic vessel, if a thick vascular wall cannot be identified	No agreement (50.0%)
6	D2-40 positive vessel should be interpreted as lymphatic vessel regardless of the presence of endothelium	No agreement (37.5%)
7	D2-40 positive vessel without endothelium should not be interpreted as lymphatic vessel	No agreement (12.5%)
8	D2-40 negative vessel suspected as a lymphatic vessel in H&E staining should be interpreted as lymphatic vessel	No agreement (37.5%)
9	D2-40 positive cells covering all of the circumference surrounding the tumour cluster is the requirement for lymphatic vessel invasion	No agreement (0%)
10	D2-40 positive cells covering more than half of the circumference surrounding the tumour cluster is the requirement for lymphatic vessel invasion	No agreement (62.5%)
11	D2-40 positive endothelial cells covering all of the circumference surrounding the tumour cluster is the requirement for lymphatic vessel invasion	No agreement (0%)
12	D2-40 positive endothelial cells covering more than half of the circumference surrounding the tumour cluster is the requirement for lymphatic vessel invasion	Agreement (87.5%)
13	Tumour invasion into the D2-40- stained vessel is determined as lymphatic vessel invasion	Agreement (100%)

BLI, blood and lymphatic vessel invasion.

more consistent diagnosis. Pathological assessment is generally inexpensive and is available at many hospitals. So introducing a standardised pathological diagnosis can be a major contribution to current medical practice. So far, poor agreement has been reported on BLI diagnosis in many organs and conducting a multicentre study using BLI may be difficult. There are some criteria suggested by pathologists on vascular invasion and some of them

were incorporated into our criterion.^{23 24} While findings of H&E-stained slides should be further reviewed to search for findings with high concordance, developing objective criteria based only on H&E staining may be difficult. BLI and many pathological diagnoses are based on multiple associated histological findings. Therefore, investigation of the concordance in the histological findings associated with the diagnosis of BLI in our

Table 4 Current practice of pathological assessment at the department of pathology in different medical institutions in 2003

Institution	A	B	C	D	E	F	G	H
Number of cases	233	98	62	127	203	232	54	441
Number of colon cancer cases (%)	169 (72.5)	50 (51.0)	46 (74.2)	91 (71.7)	116 (57.1)	137 (59.1)	29 (53.7)	254 (57.6)
Number of rectal cancer cases (%)	64 (27.5)	48 (49.0)	16 (25.8)	36 (28.3)	87 (42.9)	95 (40.9)	25 (46.3)	187 (42.4)
Male patients (%)	145 (62.2)	59 (60.2)	35 (56.5)	68 (53.5)	133 (65.5)	130 (56.0)	29 (53.7)	262 (59.4)
Female patients (%)	88 (37.8)	39 (39.8)	27 (43.5)	59 (46.5)	70 (34.5)	102 (44.0)	25 (46.3)	179 (40.6)
Average age	65.0	64.2	67.4	68.0	63.4	64.3	64.4	63
Average number of blocks	20.1	34.4	4.8	6.4	8.8	18.0	6.3	8.0
Use of histochemical stainings	Some cases	All cases	None	Some cases	All cases	All cases	None	All cases
Range of histochemical stainings	Representative one block	All blocks	None	Representative one block	Blocks from largest slice of tumour	Representative one block	None	Representative one block
Use of immunohistochemical stainings	Some cases	None	None	Some cases	Some cases	Some cases	None	None
Antibody used in immunohistochemical stainings	D2-40	None	None	D2-40	D2-40, SMA	D2-40	None	None

framework was an important step. And the problem of diagnostic threshold or retraction artefacts remains unsolved and may be one of the reasons for poor concordance.⁹ Elastica-staining and D2-40 staining have been reported to be useful in detecting BLI but may not always be associated with the detection of patients with higher risk.¹⁴⁻²⁵ Review of histochemical and immunohistochemical findings in this study suggested key findings with high concordance which may improve the quality of pathological diagnosis. Although the use of these stains alone may be insufficient, it can be used in combination with diagnostic criterion. D2-40 immunostaining was seen in lymphatic endothelium and in fibroblasts. D2-40-positive endothelial cells (but not D2-40 positive cells) was another important finding with high concordance.²⁶ Although histological variation was reported in blood vessel invasion, elastica-stained internal elastic membrane is the most important feature having consistent results.²⁷ Careful attention should be paid, however, to the lesion such as myenteric plexus ganglia invasion mimicking blood vessel invasion so as not to misdiagnose as blood vessel invasion in H&E staining. Use of some additional markers may be beneficial to reduce misdiagnosis of BLI without D2-40 expression or internal elastic membrane in the future.

Most pathological criteria to date have been developed through an informal approach by group experts in various

scientific committees. A more standardised approach needs to be taken to develop pathological criteria to be used in all kinds of clinical or pathological settings. By analysing the current practice of pathologists and using the Delphi method, we have developed a framework for a new pathological diagnostic criterion. Although it still may not be sufficient to be used in multicentre trials, significant improvement over current practice is expected. We invite other pathologists' comment for its further revision and refinement. Routine elastica staining is low in cost and can be easily adopted by pathologists at different sites.²⁸ The applications of the present study's criterion to the daily diagnosis of BLI will likely result in the accumulation of more consistent results regarding blood vessel invasion. Although routine use of our criteria of lymphatic vessel invasion may not be feasible for advanced CRC where multiple immunostaining is required for the assessment, it may be useful for endoscopically resected pT1 CRC which is small in size and only few blocks are required.²⁹ The present report gives a set of criteria hopefully allowing a more consistent identification and reporting of BLI in CRC, and gives a template for the development of such diagnostic criteria that can be used in other areas of diagnostic pathology. Based on the framework that we propose, a more objective and consensus-based pathological diagnostic system can be created in many areas of diagnostic pathology.

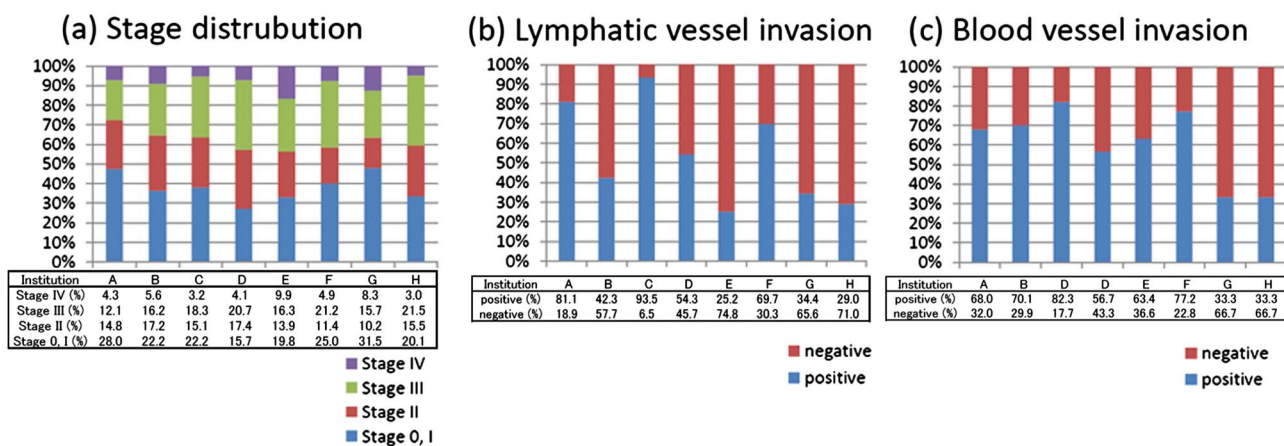


Figure 3 (A) Stage distribution of 1450 surgically resected colorectal cancer (CRC) cases among eight hospitals. (B) Distribution of positive cases of lymphatic vessel invasion among 1450 surgically resected CRC cases from eight hospitals. (C) Distribution of positive cases of blood vessel invasion among 1450 surgically resected CRC cases from eight hospitals.

Box 1 Established diagnostic criterion of blood and lymphatic vessel invasion (BLI) in Japanese society for cancer of the colon and rectum (JSSCR)

Definition

Lymphatic vessel invasion is defined as invasion of tumour cells into lymphatic vessels.

Blood vessel invasion is defined as invasion of tumour cells into blood vessels.

Assessment

Scanning at 4× magnification should be used to identify the suspected lesion. Then, further assessment should be made at higher magnification.

BLI should not be determined in lesions presenting spicula between the tumour nest and stroma.

Assessment of lymphatic vessel invasion

D2-40 positive vessel invasion should be determined as lymphatic vessel invasion, and the presence of D2-40 positive endothelial cells covering more than half of the circumference surrounding the tumour cluster should be the basis for diagnosis.

An indistinguishable lesion should not be determined as lymphatic vessel invasion.

Blood vessel invasion

In elastica staining, thick arteries surrounded by the tumour cluster should be identified. If elastica-stained internal elastic membrane covering more than half of the circumference surrounding the tumour cluster is present, the lesion should be diagnosed as blood vessel invasion.

Elastica positive vessel invasion should be determined as blood vessel invasion, and the presence of elastica-stained internal elastic membrane covering more than half of the circumference surrounding the tumour cluster should be the basis for diagnosis.

When the presence of elastica-stained internal elastic membrane covering more than half of the circumference surrounding the tumour cluster is identified, the lesion should be diagnosed as blood vessel invasion, even in the absence of accompanying artery, vascular structure or space.

Take home messages

- Current practice of pathology assessment was varied among institutions in Japan.
- Concordance was low for the pathological diagnosis of blood and lymphatic vessel invasion (BLI) in colorectal cancer, and was not any better when histochemical/immunohistochemical staining was provided.
- All histological findings associated with BLI from H&E staining were poor in agreement. However, observation of elastica-stained internal elastic membrane covering more than half of the circumference surrounding the tumour cluster as well as the presence of D2-40-stained endothelial cells covering more than half of the circumference surrounding the tumour cluster showed high concordance.
- Based on this observation, we developed a framework for pathological diagnostic criterion, using the Delphi method, which may serve as the basis for creating a standardised procedure for pathological diagnosis.

Author affiliations

- ¹Pathology Division, Research Center for Innovative Oncology, National Cancer Center Hospital East, Kashiwa, Chiba, Japan
- ²Department of Pathology, National Defence Medical College, Saitama, Japan
- ³Department of Diagnostic Pathology, Kurume University Hospital, Kurume, Fukuoka, Japan
- ⁴Department of Pathology, Kurume University School of Medicine, Kurume, Fukuoka, Japan
- ⁵Department of Pathology, Kyorin University Graduate School of Medicine, Tokyo, Japan
- ⁶Department of Pathology, Tokyo Metropolitan Komagome Hospital, Tokyo, Japan
- ⁷Division of Organ Pathology, Department Microbiology and Pathology, Faculty of Medicine Tottori University, Tottori, Japan
- ⁸Pathology Division, National Cancer Center Hospital, Tokyo, Japan
- ⁹Department of Pathology, Graduate School of Medicine and Dental Sciences, Niigata University, Niigata, Japan
- ¹⁰Clinical Trial Section, Research Center for Innovative Oncology, National Cancer Center Hospital East, Chiba, Japan

Acknowledgements The authors thank Sachiko Fukuda for her excellent technical assistance. We also thank Yoshiko Ohnuma and Motoko Suzaki for their secretarial help with the consensus meetings and the distribution of the slides. We also thank Mari Kanai and Yuri Kitayama for excellent English support.

Contributors Conception and design: MK, SN and AO. Administrative support: MK and AO. Collection and assembly of data: MK, SN and AO. Data analysis and interpretation: All authors. Manuscript writing: All authors. Final approval of manuscript: All authors

Funding This work was supported by the Japanese Society for Cancer of the Colon and Rectum (JSSCR).

Competing interests None.

Ethics approval This study was approved by the local research ethics committee of the National Cancer Center Hospital (No. 2010-100).

Provenance and peer review Not commissioned; externally peer reviewed.

Open Access This is an Open Access article distributed in accordance with the Creative Commons Attribution Non Commercial (CC BY-NC 3.0) license, which permits others to distribute, remix, adapt, build upon this work non-commercially, and license their derivative works on different terms, provided the original work is properly cited and the use is non-commercial. See: <http://creativecommons.org/licenses/by-nc/3.0/>

REFERENCES

- 1 Brown CE, Warren S. Visceral metastasis from rectal carcinoma. *Surg Gynecol Obstet* 1938;66:611–21.
- 2 Compton CC, Fielding LP, Burgart LJ, et al. Prognostic factors in colorectal cancer. *Arch Pathol Lab Med* 2000;124:979–94.
- 3 Sobin LH, Wittekind CH. *TNM classification of malignant tumors*. 5th edn. New York, USA: Wiley-Liss, 1997.
- 4 Sobin LH, Gospodarowicz MK, Wittekind CH, eds. *TNM classification of malignant tumors*. 7th edn. New York, USA: Wiley Blackwell, Inc., 2009.
- 5 Dotan E, Cohen SJ. Challenges in the management of stage II colon cancer. *Semin Oncol* 2011;38:511–20.
- 6 Newland RC, Dent OF, Chapuis PH, et al. Survival after curative resection of lymph node negative colorectal carcinoma. A prospective study of 910 patients. *Cancer* 1995;76:564–71.
- 7 Akishima-Fukasawa Y, Ishikawa Y, Akasaka Y, et al. Histopathological predictors of regional lymph node metastasis at the invasive front in early colorectal cancer. *Histopathology* 2011;59:470–81.
- 8 Hoda SA, Hoda RS, Merlin S, et al. Issues relating to lymphovascular invasion in breast carcinoma. *Adv Anat Pathol* 2006;13:308–15.
- 9 Harris EI, Lewin DN, Wang HL, et al. Lymphovascular invasion in colorectal cancer: an interobserver variability study. *Am J Surg Pathol* 2008;32:1816–21.
- 10 Fan L, Mac MT, Frishberg DP, et al. Interobserver and intraobserver variability in evaluating vascular invasion in hepatocellular carcinoma. *J Gastroenterol Hepatol* 2010;25:1556–61.
- 11 Walgenbach-Bruenagel G, Tolba RH, Varnai AD, et al. Detection of lymphatic invasion in early stage primary colorectal cancer with the monoclonal antibody D2-40. *Eur Surg Res* 2006;38:438–44.
- 12 Yamauchi C, Hasebe T, Iwasaki M, et al. Accurate assessment of lymph vessel tumor emboli in invasive ductal carcinoma of the breast according to tumor areas, and their prognostic significance. *Hum Pathol* 2007;38:247–59.
- 13 Kawaura K, Fujii S, Murata Y, et al. The lymphatic infiltration identified by D2-40 monoclonal antibody predicts lymph node metastasis in submucosal invasive colorectal cancer. *Pathobiology* 2007;74:328–35.

- 14 Ito M, Moriya T, Ishida T, *et al.* Significance of pathological evaluation for lymphatic vessel invasion in invasive breast cancer. *Breast Cancer* 2007;14:381–7.
- 15 Roxburgh CS, McMillan DC, Anderson JH, *et al.* Elastica staining for venous invasion results in superior prediction of cancer-specific survival in colorectal cancer. *Ann Surg* 2010;252:989–97.
- 16 Powell C. The Delphi technique: myths and realities. *J Adv Nurs* 2003;41:376–82.
- 17 Dirschmid KW, Sterlacci W, Oellig F, *et al.* Absence of extramural venous invasion is an excellent predictor of metastasis-free survival in colorectal carcinoma stage II—a study using tangential tissue sectioning. *J Clin Pathol* 2012;65:619–23.
- 18 Klimstra DS, Modlin IR, Adsay NV, *et al.* Pathology reporting of neuroendocrine tumors: application of the Delphi consensus process to the development of a minimum pathology data set. *Am J Surg Pathol* 2010;34:300–13.
- 19 Mahler DA, Selecky PA, Harrod CG, *et al.* American College of Chest Physicians consensus statement on the management of dyspnea in patients with advanced lung or heart disease. *Chest* 2010;137:674–91.
- 20 Zafar SY, Currow DC, Cherny N, *et al.* Consensus-based standards for best supportive care in clinical trials in advanced cancer. *Lancet Oncol* 2012;13:e77–82.
- 21 Chen B, Seel L. A macro to calculate kappa statistics for categorizations by multiple raters. In *Proceeding of the 30th Annual SAS Users Group International Conference 2005*. <http://www2.sas.com/proceedings/sugi30/155-30.pdf> (accessed 26 Oct 2011).
- 22 Sejben I, Bori R, Cserni G. Venous invasion demonstrated by orcein staining of colorectal carcinoma specimens is associated with the development of distant metastasis. *J Clin Pathol* 2010;63:575–8.
- 23 Minsky B, Mies C. The clinical significance of vascular invasion in colorectal cancer. *Dis Colon Rectum* 1989;32:794–803.
- 24 Talbot IC, Ritchie S, Leighton M, *et al.* Invasion of veins by carcinoma of rectum: method of detection, histological features and significance. *Histopathology* 1981;5:141–63.
- 25 Messenger DE, Driman DK, McLeod RS, *et al.* Current practice patterns among pathologists in the assessment of venous invasion in colorectal cancer. *J Clin Pathol* 2011;64:983–89.
- 26 Kawase A, Ishii G, Nagai K, *et al.* Podooplanin expression by cancer associated fibroblasts predicts poor prognosis of lung adenocarcinoma. *Int J Cancer* 2008;123:1053–9.
- 27 Sato T, Ueno H, Mochizuki H, *et al.* Objective criteria for the grading of venous invasion in colorectal cancer. *Am J Surg Pathol* 2010;34:454–62.
- 28 Abdulkader M, Abdulla K, Rakha E, *et al.* Routine elastic staining assists detection of vascular invasion in colorectal cancer. *Histopathology* 2006;49:487–92.
- 29 Nivatvongs S, Rojanasakul A, Reiman HM, *et al.* The risk of lymph node metastasis in colorectal polyps with invasive adenocarcinoma. *Dis Colon Rectum* 1991;34:323–8.