



OPEN ACCESS

Clinicopathological characteristics and genetic variations of uterine tumours resembling ovarian sex cord tumours

Shan Ye ,^{1,2,3} Jing Wu,^{1,2,3} Lingli Yao,^{1,2} Jie He^{1,2,3}

¹Department of Pathology, The First Affiliated Hospital of USTC, Division of Life Sciences and Medicine, University of Science and Technology of China, Hefei, Anhui, China

²Intelligent Pathology Institute, Division of Life Sciences and Medicine, University of Science and Technology of China, Hefei, Anhui, China

³Department of Pathology, Anhui Provincial Cancer Hospital, Hefei, Anhui, China

Correspondence to

Professor Jie He, Department of Pathology, The First Affiliated Hospital of USTC, Division of Life Sciences and Medicine, University of Science and Technology of China, Hefei, Anhui, China; hejie23@ustc.edu.cn

Received 29 January 2021

Accepted 3 July 2021

Published Online First

4 August 2021

ABSTRACT

Aims To investigate the clinicopathological and molecular characteristics of uterine tumours resembling ovarian sex cord tumours (UTROSCTs) and the value of molecular diversity in the clinical diagnosis and treatment.

Methods Five patients with UTROSCT were enrolled, and their clinical data, pathological morphologies, immunophenotypes and molecular features were analysed. Fluorescence in situ hybridisation for *NCOA1*, *NCOA2*, *NCOA3*, *JAZF1* and *PHF1* and next-generation sequencing for 27 homologous recombination/repair (HRR) pathway genes were performed on five and three UTROSCT specimens, respectively.

Results All five patients were treated for abnormal uterine bleeding and grossly presented with intrauterine polyps. Under a microscope, tumour cells grew diffusely and presented a cordlike arrangement and glandular duct-like structures, with nuclei ranging from round to oval, vesicular chromatin and visible nucleoli in some cases. The mitotic count was less than 3/10 high-power fields. Immunohistochemistry showed sex cord, epithelial cell and smooth muscle cell biomarkers and diffuse, strong staining for B cell lymphoma-2 (BCL-2). *NCOA1* and *NCOA3* rearrangements were identified in 80% (4/5) of the cases. *JAZF1* and *PHF1* rearrangements were not detected in any of five patients. HRR pathway gene mutations were detected in all three patients, including *FANCE*, *ATR* and *ARID1A* mutations in one case each.

Conclusion UTROSCT is a rare mesenchymal tumour, and biopsy specimens are easily misdiagnosed. UTROSCT diagnosis requires the combined use of biomarkers and molecular detection. BCL-2 has potential diagnostic value as a marker. UTROSCT can have mutations related to the HRR pathway, suggesting that this tumour type may be sensitive to platinum/poly (ADP-ribose) polymerase inhibitors.

INTRODUCTION

Uterine tumour resembling ovarian sex cord tumour (UTROSCT) is a rare type of tumour with unclear origins and is defined histologically by sex cord-like growth patterns, such as sheets, nests, trabeculae, cords or tubules, with/without Sertoli-like or Leydig-like components, and immunohistochemically by variable sex cord markers in addition to epithelial, myogenic and sex hormone markers.^{1–4} UTROSCTs are most common in perimenopausal and postmenopausal women, with an average age of approximately 50 years, and the main clinical presentation is abnormal uterine bleeding and/or

abdominal pain.^{1–5} Due to the low incidence, our understanding of UTROSCT is very limited, and it is prone to misdiagnosis.

Homologous recombination/repair (HRR) is an important repair method for DNA double-strand damage to maintain the integrity of the genome and ensure the transmission of genetic information in high fidelity. HRR is a complex signalling pathway, and *BRCA1* and *BRCA2* are the key proteins. Mutations in HRR-related genes can cause homologous recombination deficiency (HRD) and lead to genomic instability, and tumour cells often use HRR to prevent cell apoptosis.⁶ However, when tumour cells develop HRD and poly (ADP-ribose) polymerase (PARP) is inhibited, a ‘synthetic lethal’ effect will occur, and tumours with HRD are more sensitive to platinum/PARP inhibitors.^{6,7}

UTROSCTs appear to have low malignant potential. However, cases with recurrence and even metastasis to remote sites have been reported.^{7–9} Therefore, for patients with UTROSCT who cannot tolerate surgery or experience metastasis or recurrence, other potential treatments must be identified. This study attempted to further analyse the nature of this tumour by studying its clinicopathological characteristics and gene variations to provide a basis for clinical diagnosis and prognostic prediction.

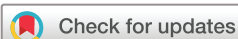MATERIALS AND METHODS

Clinical data

Five patients aged 39–65 years who were diagnosed with UTROSCT between 2014 and 2020 were enrolled in the study. These patients sought treatment due to abnormal uterine bleeding, and pathological sections were reviewed by two senior pathologists.

Immunohistochemical staining

All specimens were fixed in 3.7% neutral formalin and embedded in paraffin, and 20 consecutive sections were generated for H&E and immunohistochemical staining. Immunohistochemistry was performed using a BenchMark XT automated slide stainer (Roche, the USA). Four primary antibodies came in ready-to-use working solutions: cluster of differentiation 10 (CD10, rabbit monoclonal antibodies (mAb), SP67, Roche), oestrogen receptor (ER, rabbit mAb, SP1, Roche), progesterone receptor (PR, rabbit mAb, 1E2, Roche) and smooth muscle actin (SMA, mouse mAb, 1A4, MXB Biotechnologies, Fuzhou, China). Other primary



© Author(s) (or their employer(s)) 2022. Re-use permitted under CC BY-NC. No commercial re-use. See rights and permissions. Published by BMJ.

To cite: Ye S, Wu J, Yao L, et al. *J Clin Pathol* 2022;**75**:776–781.

antibodies, against pan-cytokeratin (CKpan, mouse mAb, AE1/mAb3), epithelial membrane antigen (EMA, mouse mAb, GP1.4), B cell lymphoma-2 (BCL-2, mouse mAb, bcl/100/D5), α -inhibin (mouse mAb, AMY82), calretinin (rabbit polyclonal antibody), steroidogenic factor-1 (SF-1, mouse mAb, OT1H2), Wilms' tumour 1 (WT-1, mouse mAb, 6F-H12), cluster of differentiation 99 (CD99) (rabbit mAb, EP8), desmin (rabbit mAb, EP15), h-caldesmon (rabbit mAb, EP19) and antigen Ki-67 (mouse mAb, UMAB107), were purchased from ZSGB Biotech, Beijing, China. The secondary antibody was the Roche universal horseradish peroxidase-labelled antibody mixture (goat anti-mouse IgG, goat anti-mouse IgM and goat anti-rabbit). Primary antibodies were conjugated using a cocktail of enzyme-labelled secondary antibodies. Diaminobenzidine was used for colour development. Haematoxylin was used for nuclear counterstaining.

Fluorescence in situ hybridisation (FISH)

Five tumour tissue samples were subjected to FISH to identify molecular rearrangements of *NCOA1*, *NCOA2*, *NCOA3*, *JAZF1* and *PHF1* (all from Guangzhou Anbiping Pharmaceutical Technology, China). FISH was performed as described previously.⁵ Briefly, the unstained slides were deparaffinised, pretreated and hybridised to denatured probes. Then, after more than 6 hours of incubation at 37°C, the slides were washed and counterstained with diaminidine phenyl indole (DAPI), mounted and analysed using a Zeiss fluorescence microscope (Olympus BX51, Tokyo, Japan).

Next-generation sequencing (NGS)

Tumour tissue samples and the corresponding paracancerous tissues collected over the last 3 years from three patients with UTROSCT were subjected to multigene sequencing of 27 HRR pathway-related genes (sequencing was completed by Shanghai Zhengu Biotechnology, China): *BRCA1*, *BRCA2*, *PIK3CA*, *KRAS*, *NRAS*, *BRAF*, *ATM*, *ATR*, *BARD1*, *BRIP1*, *CHEK2*, *CTNNB1*, *FANCA*, *FANCC*, *FANCD2*, *FANCE*, *FANCF*, *PTEN*, *MRE11A*,

NBN, *PALB2*, *PPP2R1A*, *RAD50*, *RAD51*, *RAD51C*, *RAD51D* and *ARID1A*. The average sequencing depth was 3000X, and the on-target rates were greater than 95%. The obtained mutations were filtered to retain only non-synonymous mutations, stop-gain mutations, frameshift mutations and splicing mutations. The common mutations were filtered out according to the frequency in the population. Finally, the mutations that impaired protein function, based on the results of the prediction software, were retained.

RESULTS

Clinical characteristics

As shown in table 1, the ages of the patients ranged from 39 to 65 years, with a median age of 53 years. The clinical manifestations included two cases of postmenopausal vaginal bleeding (cases 2 and 3) and other three cases of increased menstrual bleeding and prolonged periods. B-mode ultrasound suggested hypoechoic intrauterine nodules. One patient underwent hysteroscopic electrical resection (case 4), and other four patients underwent hysterectomy and bilateral adnexectomy. In general, two patients had intramural nodules protruding into the uterine cavity; two patients had intrauterine polypoid masses with a greyish-brown section, the texture of which was soft to slightly tough, and some of the polyps were lobulated with visible borders with the myometrium; one patient had a fragmented cordlike tissue (case 4), and the tumour size was 1.5–5 cm in diameter.

Histological characteristics

Under low magnification, tumor cells were arranged in a nested, trabecular, cord, reticular (figure 1A), glandular (figure 1B), small tubular and Call-Exner body-like follicular appearance (figure 1C), consisting of epithelial-looking cells and spindle-shaped cells, with scant interstitial hyaline degeneration. Under high magnification, the nuclei were oval, overlapping and without nuclear grooves, and the

Table 1 Clinical and pathological features of five patients with UTROSCT

	Case 1	Case 2	Case 3	Case 4	Case 5
Age	Early 50s	Early 60s	Early 60s	Nearly 40 years	Nearly 40 years
Symptoms	Irregular vaginal bleeding in the past 2 years	Menopause for 10 years and irregular vaginal bleeding 4 months earlier	Menopause for 22 years, irregular vaginal bleeding 14 days before admission	Increased menstrual bleeding and with the menstrual period extending for half a year	Increased menstrual bleeding for more than 3 months
Ultrasonic examination	Hypoechoic area on the posterior wall of the uterus with protrusion into the uterine cavity	Hypoechoic protrusion on right uterine wall with clear boundary	Not available	Hypoechoic intrauterine nodules	Consider endometrial polyps
General	Intramural nodules protruding into the uterine cavity, 4.5 cm in diameter	Intrauterine polypoid masses, 5 cm in diameter	Intramural nodules with polypoid bulging of the uterine cavity, 4 cm in diameter	Submucosal elevation, 3 cm in diameter (fragment tissue)	Polypoid masses, 1.5 cm in diameter
Surgical approach	Hysterectomy and bilateral adnexectomy	Hysterectomy and bilateral adnexectomy	Hysterectomy and bilateral adnexectomy	Electrical resection	Hysterectomy and bilateral adnexectomy
Muscular invasion	Tongue-like infiltration	Focal infiltration	Focal infiltration	Focal infiltration	Focal infiltration
Nucleolus	Yes	Yes	None	None	None
Necrosis	None	None	Yes	None	None
Mitotic count (/10 HPF)	2	1	1	0	0
Comorbidities	None	Leiomyoma	Leiomyoma	Endometrial polyps	Multiple endometrial polyps
Medical history	None	Leiomyoma resection 20 years ago	Diabetes, taking metformin	None	None

HPF, high-power field; UTROSCT, tumours resembling ovarian sex cord tumour.

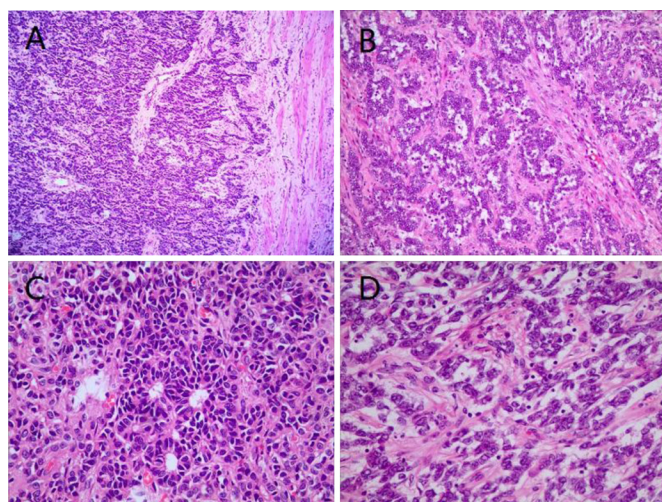


Figure 1 Microscopic characteristics of tumours resembling ovarian sex cord tumour. (A) The tumour was reticulated, and the boundary with the muscular layer was not clear, H&E $\times 100$; (B) the tumour showed an adenoid arrangement and interstitial fibrosis, H&E $\times 200$; (C) the tumour was arranged in a Call-Exner corpus-like pattern, H&E $\times 200$; (D) small nucleoli were observed in some cases, H&E $\times 400$.

nucleoli were not obvious in three cases and were visible in two cases (figure 1D). The mitotic count was 0–2/10 high-power fields. Borders of the myometrium were unclear in all five patients (figure 1), which were observed even in hysteroscopic resection specimens. One patient showed obvious tongue-like infiltration (case 1) without vascular involvement, and haemorrhage and necrosis were noted on the surface of the tumour in one case (case 3). Two patients had endometrial polyps (cases 4 and 5), and two patients had uterine leiomyomas.

Table 2 Immunohistochemical results of five patients with UTRSCT

	Case 1	Case 2	Case 3	Case 4	Case 5
CK	1+	1+	1+	2+	2+
WT-1	–	–	3+	–	2+
CD99	2+	2+	2+	2+	–
CR	2+	2+	2+	–	2+
α -Inhibin	–	1+	–	–	–
SF-1	–	2+	2+	–	2+
EMA	–	–	–	–	–
Desmin	–	2+	–	2+	1+
SMA	2+	1+	1+	3+	–
h-Caldesmon	2+	2+	2+	2+	1+
BCL-2	3+	3+	3+	3+	3+
ER	1+	1+	2+	3+	2+
PR	3+	3+	3+	3+	2+
CD10	1+	1+	1+	1+	–

‘–’ indicates negativity; ‘1+’ denotes weak or focal positivity, with a number of positive cells <25%; ‘2+’ indicates moderate positivity, with a number of positive cells of 25%–75%; ‘3+’ denotes diffuse strong positivity, with a number of positive cells >75%.

BCL-2, B cell lymphoma-2; CD10, cluster of differentiation 10; CD99, cluster of differentiation 99; CK, cytokeratin; EMA, epithelial membrane antigen; ER, oestrogen receptor; PR, progesterone receptor; SF-1, steroidogenic factor-1; SMA, smooth muscle actin; UTRSCT, tumours resembling ovarian sex cord tumour; WT-1, Wilms’ tumour 1.

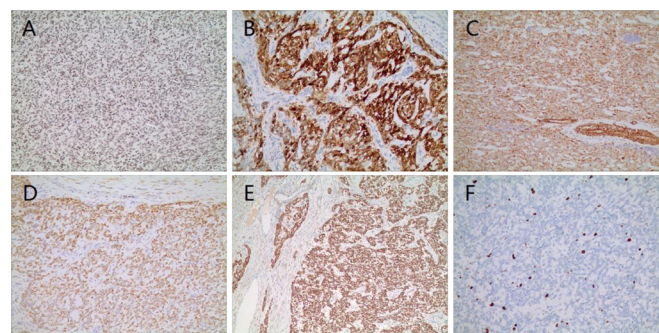


Figure 2 Immunohistochemical staining by the Envision method. (A) Steroidogenic factor-1 is positive in tumour cell nuclei ($\times 400$); (B) calretinin was diffusely positive in tumour cell cytoplasm and nuclei ($\times 200$); (C) h-caldesmon was diffusely positive in tumour cell cytoplasm and was positive in thick-walled blood vessels in the internal control ($\times 200$); (D) pan-cytokeratin was diffusely positive in tumour cell cytoplasm ($\times 100$); (E) B cell lymphoma-2 (BCL-2) was diffusely positive in tumour cell cytoplasm but negative in the peripheral muscular layer and blood vessels ($\times 200$); (F) Ki-67 was sporadically positive in tumour cell cytoplasm.

Immunohistochemical characteristics

As shown in table 2, more than two sex cord markers were expressed in all five patients. The positive expression rates of α -inhibin, WT-1, SF-1 (figure 2A), calretinin (figure 2B) and CD99 were 1/5, 2/5, 3/5, 4/5 and 4/5, respectively. All patients expressed one or more smooth muscle markers, and the positive expression rates of desmin, SMA, and h-caldesmon (figure 2C) were 3/5, 4/5 and 5/5, respectively. CKpan (figure 2D), BCL-2 (figure 2E), ER and PR expressions were observed and EMA was negative in all five patients. The CD10-positive rate was 4/5, and the positive rate of Ki-67 was 5%–15% in all five patients (figure 2F).

Molecular features

NCOA1 (figure 3A) gene breaks were detected in cases 1, 2 and 3. NCOA3 gene breaks were detected in case 4. Case 5 did not have any of these gene breaks. NCOA2, JAZF1 (figure 3B) and PHF1 gene breaks were not detected in any of the five patients.

Somatic pathological mutations were detected in three patients. FANCE gene Exon 1 pW19X stop-gain mutation (G–A) was detected in case 4, resulting in the acquisition of a stop codon. The ATR gene Exon 9 pI710Yfs5 frameshift mutation (AT–A) was detected in case 3. The ARID1A gene Exon 1 pP21del non-frameshift mutation (CCCG–C) was detected in case 2. No suspected pathogenic germline mutations in the HRR-related pathway genes were found in the three patients.

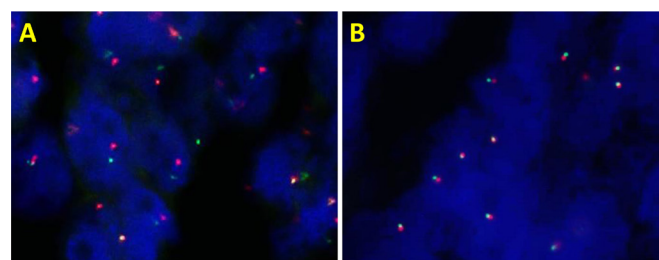


Figure 3 Fluorescence in situ hybridisation (FISH) test features of tumours resembling ovarian sex cord tumour. (A) FISH showing a separated signal for NCOA1 (case 3); (B) FISH showing no separated signal for JAZF1 (case 1).

Treatment and follow-up

Four patients underwent hysterectomy and bilateral adnexectomy, one patient underwent hysteroscopic resection and all five patients were followed up. None of the patients received further postoperative treatment. The follow-up time was 4–72 months (average 20 months), and no recurrence or metastasis was noted.

DISCUSSION

Uterine tumours with sex cord-like elements were first proposed by Clement *et al* in 1976.¹⁰ Based on their biological behaviour, this type of tumour was classified into two groups. Group I is endometrial stromal tumours with foci of sex cord-like elements (sex cord elements <50%), which usually show recurrence and metastasis. Group II is composed predominantly or exclusively of sex cord-like elements (>50%). They are mostly benign and generally do not recur or metastasise. In the 2003 version of the WHO classification, group II was included in the 'other' types of mesenchymal tumours, and the diagnosis was uterine sex cord-like tumour. In the 2014 version of the WHO classification, group I was included in the low-grade endometrial stromal tumours, while group II tumours were individually categorised as UTROSCT. This emphasised that only when tumours lack classic endometrial stromal tumour elements can this diagnosis be made.¹¹

Compared with low-grade endometrial stromal tumours with sex cord-like differentiation, UTROSCT lacks the *JAZF1-SUZ12* (two zinc finger protein genes) fusion gene or the *PHF1* rearrangement.¹² Both *JAZF1* and *PHF1* were absent in all five of our patients, which is useful for distinguishing UTROSCT from low-grade endometrial stromal tumours with sex cord-like differentiation. In addition, UTROSCT lacks the *FOXL2* mutation in adult granulosa cell tumours of the ovary and has the *dicer 1*, ribonuclease III mutations in Sertoli-Leydig cell tumours, although UTROSCT can express *FOXL2* as detected by immunohistochemistry.¹³

UTROSCT may represent an independent tumour unrelated to endometrial stromal tumours and ovarian sex cord-stromal tumours. Dickson *et al*¹⁴ recently reported that UTROSCT includes *NCOA2* or *NCOA3* gene fusions, suggesting that UTROSCT is an independent tumour. Goebel *et al*⁵ also reported that UTROSCTs show *NCOA2-3* gene fusions, and novel rearrangements involving *NCOA1* were identified. In all, 81.8% (18/22) of cases showed *NCOA1-3* fusions, emphasising that UTROSCT is a distinct entity and that the detection of these gene fusions is useful in differentiating this tumour from other entities. In our study, *NCOA1* and *NCOA3* were identified in 80% (4/5) of our patients, which provides strong support for the diagnosis of UTROSCT.

The immunohistochemical features of UTROSCT are the multiple phenotypes of epithelial cells, smooth muscle cells, sex cord markers and hormone receptors.¹ Among the five cases reported here, at least two of the sex cord markers α -inhibin, calretinin, SF-1, CD99 and WT-1 were positive. Among them, α -inhibin and SF-1 are currently the most specific markers for the diagnosis of ovarian sex cord-stromal tumours. Stewart *et al*¹⁵ compared UTROSCT with other uterine tumours with sex cord differentiation and found that the sensitivity of calretinin in the diagnosis of UTROSCT was 100%, the specificity was 80% and the sensitivity and specificity of SF-1 were 50% and 100%, respectively. In our cases, three were positive for SF-1, which was consistent with the above reports, suggesting that sex cord differentiation is a concomitant feature in uterine tumours but is intrinsic in UTROSCT. Cytokeratin (CK) was positive, and

EMA was negative in all five cases, consistent with the traits of ovarian sex cord-stromal tumours.¹⁶ The positive expression of CK can easily lead us to misdiagnose it as an epithelial malignant tumour, especially in biopsy specimens. In these cases, EMA should be included for diagnosis.

We inadvertently found strong, diffuse BCL-2 positivity in one patient with UTROSCT, so we retrospectively performed immunohistochemistry for BCL-2 in the other four cases and surprisingly found that all tumours diffusely and strongly expressed BCL-2. In 2003, Wang *et al*¹⁷ also reported diffusely and strongly expressed BCL-2 in one patient with UTROSCT. This patient had a translocation on chromosomes t(4; 18) (q21.1; q21.3) and t(x; 6) (p22.3; q23.1), which the authors suggest is associated with the inclusion of important oncogenes such as BCL-2 and *MALT1* on chromosome 18. BCL-2 antagonises cell apoptosis,¹⁸ but the mechanism is not clear. BCL-2 overexpression may have potential value in the diagnosis of UTROSCT; however, more cases need to be investigated.

The differential diagnosis included the following

1. Epithelioid leiomyoma: Epithelioid leiomyoma has similarities to UTROSCT, and both show clear boundaries, soft textures, yellow or grey cross sections, round or polygonal tumour cells and cells arranged in tufts and cords under a microscope. However, epithelioid leiomyomas are commonly associated with the transition of spindle-shaped smooth muscle cells, and they lack the UTROSCT-like sex cord-like phenotype based on immunohistochemistry.
2. Endometrial stromal sarcomas or endometrial stromal nodules with sex cord differentiation: Histologically, a typical area of an endometrial stromal tumour can always be found, such as characteristic small arteries, proliferation of endometrial stromal cells and diffusely positive CD10, while its sex cord-differentiated areas are indistinguishable from UTROSCT. When the two are difficult to distinguish, molecular detection can be performed. Endometrial stromal tumours show specific t(7;17) (p15;q21) translocations, resulting in *JAZF1-SUZ12* gene fusion.
3. Endometrial cancer (epithelial malignant tumour): In biopsy specimens, the epithelioid-like structure of UTROSCT, broad-spectrum CK positivity and clinical history of abnormal vaginal bleeding can easily lead us to misdiagnose it as an epithelial malignant tumour, but misdiagnosis can be avoided with the careful observation of the mitotic figures and nuclear heterogeneity.

Among these five patients with UTROSCT, two fertile patients also had endometrial polyps, including one case of multiple polyps, and two menopausal patients also had multiple uterine leiomyomas. Is the occurrence of UTROSCT related to a high oestrogen level? Some patients with UTROSCT have had breast cancer and tamoxifen treatment histories, so more clinical data need to be accumulated.^{19 20}

For patients with UTROSCT, surgical intervention is an effective treatment, and the prognosis of most patients is good. However, in a study with long-term follow-up (average 39 months) published in 2017, 23.5% (8/34) of the patients had recurrence and metastasis.²¹ Therefore, UTROSCT has obvious malignant potential, with no reliable prognostic factor in histology. The adjuvant treatment approaches for these eight patients with recurrence were different, and eventually, three patients died of this tumour. It has recently been found that UTROSCT has the recurrent fusion of *NCOA2* or *NCOA3*, its partner genes are *ESR1* and *GREB1*¹⁴ and recurrence has been associated with *GREB1*,⁵ which underscores the possible value of molecular detection in predicting prognosis. Therefore, for

patients with UTROSCT who cannot tolerate surgery or experience metastasis or recurrence, choosing an effective treatment is a new challenge. However, there is very little evidence to aid decision making.

HRR is an important repair method for DNA double-strand damage, and defects in this pathway usually lead to tumorigenesis.⁶ HRD has been observed in some patients with ovarian cancer or breast cancer,²² especially in patients with high-grade ovarian serous carcinoma,²³ who are sensitive to platinum-containing drugs and PARP inhibitors.^{6,24} HRR involves multiple steps; in addition to *BRCA1/2*, mutations in other HRR-related genes can also cause HRD and lead to genome instability.²⁵ Pellegrino *et al*²⁶ performed germline and systemic mutation sequencing of 13 HRR-related genes in 390 cases of ovarian cancer and found that patients with germline or systemic HRR-related gene mutations were highly correlated with platinum-based treatment sensitivity and good prognosis. For this reason, some researchers put forward the concept of 'BRCAness', which describes HRD that does not have *BRCA* mutations but has a phenotype similar to *BRCA* mutation tumours.²⁷ Therefore, the detection of HRD needs to integrate the detection of *BRCA1/2* and other HRR-related genes to more effectively screen the population for platinum/PARP inhibitors.

With the key advances in NGS technology, NGS has expanded our understanding of HRD and related gene instability in more tumour types. To understand whether these drugs can benefit patients with UTROSCT, we detected 27 HRR pathway-related genes by NGS, and the results showed that suspected pathogenic somatic mutations were detected in all three of patients, including *FANCE*, *ATR* and *ARID1A*. *ATR* kinase is a RAD3-related protein that can directly phosphorylate the protein encoded by the tumour suppressor gene p53 and cell cycle regulatory proteins; *ATR* and its associated signalling pathways are critical to genome stability and the occurrence and development of various tumours.²⁸ *FANCE* belongs to the Fanconi anaemia complementation group and is mainly responsible for cytogenetic stability and DNA repair.²⁹ Moreover, *FANCE* is associated with sensitivity to platinum drugs in ovarian carcinoma.³⁰ To our knowledge, our discovery fills the gap in research on the HRR pathway in UTROSCT, and the results suggest that patients with UTROSCT may also be sensitive to platinum/PARP inhibitors.

Take home messages

- ⇒ Tumours resembling ovarian sex cord tumour (UTROSCT) is a rare type of tumour that requires the combined use of biomarkers and molecular detection for diagnosis.
- ⇒ Immunohistochemistry showed diffuse and strong expression of B cell lymphoma-2 (BCL-2) in all patients. BCL-2 overexpression may have potential value in the diagnosis of UTROSCT.
- ⇒ UTROSCT can have mutations related to the homologous recombination/repair pathway, suggesting the presence of repair gene instability in this tumour type, which is in line with its borderline or malignant behaviour; thus, this tumour may be sensitive to platinum/poly (ADP-ribose) polymerase (PARP) inhibitors.

Contributors SY: Manuscript writing/editing and data collection. JW: Technical assistance and data collection. LY: Technical assistance and manuscript editing. JH: Study concept and design and project development.

Funding This study was financed by the National Natural Science Foundation of China (81872055).

Competing interests None declared.

Patient consent for publication Not required.

Ethics approval Approval was obtained from the ethics committee of the First Affiliated Hospital of USTC (No: 2021-BLK-04).

Provenance and peer review Not commissioned; externally peer reviewed.

Data availability statement All data relevant to the study are included in the article

Open access This is an open access article distributed in accordance with the Creative Commons Attribution Non Commercial (CC BY-NC 4.0) license, which permits others to distribute, remix, adapt, build upon this work non-commercially, and license their derivative works on different terms, provided the original work is properly cited, appropriate credit is given, any changes made indicated, and the use is non-commercial. See: <http://creativecommons.org/licenses/by-nc/4.0/>.

ORCID iD

Shan Ye <http://orcid.org/0000-0001-6496-0893>

REFERENCES

- de Leval L, Lim GSD, Waltregny D, *et al*. Diverse phenotypic profile of uterine tumors resembling ovarian sex cord tumors: an immunohistochemical study of 12 cases. *Am J Surg Pathol* 2010;34:1749–61.
- Hurrell DP, McCluggage WG. Uterine tumour resembling ovarian sex cord tumour is an immunohistochemically polyphenotypic neoplasm which exhibits coexpression of epithelial, myoid and sex cord markers. *J Clin Pathol* 2007;60:1148–54.
- Stolnicu S, Balachandran K, Aleykutty MA, *et al*. Uterine adenomasarcomas overgrown by sex-cord-like tumour: report of two cases. *J Clin Pathol* 2009;62:942–4.
- Sutak J, Lazic D, Cullimore JE. Uterine tumour resembling an ovarian sex cord tumour. *J Clin Pathol* 2005;58:888–90.
- Goebel EA, Hernandez Bonilla S, Dong F, *et al*. Uterine tumor resembling ovarian sex cord tumor (UTROSCT): a morphologic and molecular study of 26 cases confirms recurrent NCOA1-3 rearrangement. *Am J Surg Pathol* 2020;44:30–42.
- Heeke AL, Pishvaian MJ, Lynce F, *et al*. Prevalence of homologous Recombination-Related gene mutations across multiple cancer types. *JCO Precis Oncol* 2018;2018. doi:10.1200/PO.17.00286. [Epub ahead of print: 23 07 2018].
- Moore M, McCluggage WG. Uterine tumour resembling ovarian sex cord tumour: first report of a large series with follow-up. *Histopathology* 2017;71:751–9.
- Mačák J, Dunder P, Dvořáková J, *et al*. Uterine tumors resembling ovarian sex cord tumors (UTROSCT). Report of a case with lymph node metastasis. *Cesk Patol* 2014;50:46–9.
- Umeda S, Tateno M, Miyagi E, *et al*. Uterine tumors resembling ovarian sex cord tumors (UTROSCT) with metastasis: clinicopathological study of two cases. *Int J Clin Exp Pathol* 2014;7:1051–9.
- Clement PB, Scully RE. Uterine tumors resembling ovarian sex-cord tumors. A clinicopathologic analysis of fourteen cases. *Am J Clin Pathol* 1976;66:512–25.
- Meinhold-Heerlein I, Fotopoulou C, Harter P, *et al*. The new WHO classification of ovarian, fallopian tube, and primary peritoneal cancer and its clinical implications. *Arch Gynecol Obstet* 2016;293:695–700.
- Staats PN, Garcia JJ, Dias-Santagata DC, *et al*. Uterine tumors resembling ovarian sex cord tumors (UTROSCT) lack the JAZF1-JAZ1 translocation frequently seen in endometrial stromal tumors. *Am J Surg Pathol* 2009;33:1206–12.
- Croce S, de Kock L, Boshari T, *et al*. Uterine tumor resembling ovarian sex cord tumor (UTROSCT) commonly exhibits positivity with sex cord markers FOXL2 and SF-1 but lacks FOXL2 and DICER1 mutations. *Int J Gynecol Pathol* 2016;35:301–8.
- Dickson BC, Childs TJ, Colgan TJ, *et al*. Uterine tumor resembling ovarian sex cord tumor: a distinct entity characterized by recurrent NCOA2/3 gene fusions. *Am J Surg Pathol* 2019;43:178–86.
- Stewart CJR, Crook M, Tan A. SF1 immunohistochemistry is useful in differentiating uterine tumours resembling sex cord-stromal tumours from potential histological mimics. *Pathology* 2016;48:434–40.
- Al Harbi R, McNeish IA, El-Bahrawy M. Ovarian sex cord-stromal tumors: an update on clinical features, molecular changes, and management. *Int J Gynecol Cancer* 2021;31:161–168.
- Wang J, Blakey GL, Zhang L, *et al*. Uterine tumor resembling ovarian sex cord tumor: report of a case with t(X;6)(p22.3;q23.1) and t(4;18)(q21.1;q21.3). *Diagn Mol Pathol* 2003;12:174–80.
- Matsuura K, Huang N-J, Cocce K, *et al*. Downregulation of the proapoptotic protein MOAP-1 by the UBR5 ubiquitin ligase and its role in ovarian cancer resistance to cisplatin. *Oncogene* 2017;36:1698–706.

Handling editor Mona El-Bahrawy.

- 19 Kaur K, Rajeshwari M, Gurung N, *et al.* Uterine tumor resembling ovarian sex cord tumor: a series of six cases displaying varied histopathological patterns and clinical profiles. *Indian J Pathol Microbiol* 2020;63:S81–6.
- 20 Blake EA, Sheridan TB, Wang KL, *et al.* Clinical characteristics and outcomes of uterine tumors resembling ovarian sex-cord tumors (UTROSCT): a systematic review of literature. *Eur J Obstet Gynecol Reprod Biol* 2014;181:163–70.
- 21 Moore M, McCluggage WG. Uterine tumour resembling ovarian sex cord tumour: first report of a large series with follow-up. *Histopathology* 2017;71:751–9.
- 22 Telli ML, Chu C, Badve SS, *et al.* Association of Tumor-Infiltrating Lymphocytes with Homologous Recombination Deficiency and *BRCA1/2* Status in Patients with Early Triple-Negative Breast Cancer: A Pooled Analysis. *Clin Cancer Res* 2020;26:2704–10. doi:10.3390/cancers10120506. [Epub ahead of print: 11 12 2018].
- 23 Liu YL, Selenica P, Zhou Q, *et al.* *BRCA* Mutations, Homologous DNA Repair Deficiency, Tumor Mutational Burden, and Response to Immune Checkpoint Inhibition in Recurrent Ovarian Cancer. *JCO Precis Oncol* 2020;4. doi:10.1200/PO.20.00069. [Epub ahead of print: 16 06 2020].
- 24 Pilié PG, Gay CM, Byers LA, *et al.* PARP Inhibitors: Extending Benefit Beyond *BRCA*-Mutant Cancers. *Clin Cancer Res* 2019;25:3759–71.
- 25 Byers LA, Wang J, Nilsson MB, *et al.* Proteomic profiling identifies dysregulated pathways in small cell lung cancer and novel therapeutic targets including PARP1. *Cancer Discov* 2012;2:798–811.
- 26 Pellegrino B, Mateo J, Serra V, *et al.* Controversies in oncology: are genomic tests quantifying homologous recombination repair deficiency (HRD) useful for treatment decision making? *ESMO Open* 2019;4:e480:e000480.
- 27 Nicolas E, Bertucci F, Sabatier R, *et al.* Targeting *BRCA* Deficiency in Breast Cancer: What are the Clinical Evidences and the Next Perspectives? *Cancers* 2018;10. doi:10.3390/cancers10120506. [Epub ahead of print: 11 12 2018].
- 28 Wang X, Ran T, Zhang X, *et al.* 3.9 Å structure of the yeast Mec1-Ddc2 complex, a homolog of human ATR-ATRIP. *Science* 2017;358:1206–9.
- 29 Fiesco-Roa MO, Giri N, McReynolds LJ, *et al.* Genotype-Phenotype associations in Fanconi anemia: a literature review. *Blood Rev* 2019;37:100589.
- 30 Taniguchi T, Tischkowitz M, Ameiziane N, *et al.* Disruption of the Fanconi anemia-*BRCA* pathway in cisplatin-sensitive ovarian tumors. *Nat Med* 2003;9:568–74.